



IMAGE ARTICLE

Transillumination of Testicular Hydrocele

David Bryson*

Department of Forensic Science, College of Life and Natural Sciences, University of Derby, UK

*Corresponding author: David Bryson, Department of Forensic Science, College of Life and Natural Sciences, University of Derby, Kedleston Road, DE22 1GB, UK, E-mail: D.Bryson@derby.ac.uk



Abstract

Transillumination is a useful and inexpensive clinical tool that can be used for a range of conditions including testicular hydrocele. This paper gives a brief overview of the clinical use of transillumination in general, for testicular hydroceles and guidance for photography.

Introduction

There are certain clinical conditions that can be diagnosed and visualized using light transmitted through the skin and other tissues. This paper briefly looks at the clinical use of transillumination in the literature and gives guidance for photography. The use of transillumination has been around for a long time for example from Bryant's Practice of surgery in 1873 [1] "Is it a hydrocele or a haematocele? Is it the product of inflammation or tubercular disease? Is it a new growth altogether, and if so is it innocent in its nature or malignant? Should the tumor prove translucent by transmitted light, the existence of a hydrocele may fairly be decided".

Literature Review

It has been used to look at the extent of fluid in an infant skull in the paper by Martin Johns [2] and using infrared transillumination to examine breast tissue and neonates [3] before improved resolution in ultrasound was available. Details about transillumination from a technical photographic perspective can be found in Ray's book on Scientific and Applied Imaging [4].

More recently it has been used in ophthalmology to visualize intraocular tumours [5] and in dermatology to look at the response of nails to treatment [6], as a bedside aid for differentiating meningocele from myelomeningocele [7]. As Pandita commented "The test is cheap, easily achievable and can be executed in the periphery by health care people, who do not have access to mod-

ern ultrasound machines". But also stressed that MRI was the Gold standard for diagnosing meningocele and myelomeningocele.

Transillumination for the differential diagnosis of testicular hydrocele has been covered in recent clinical literature including; Abdominoscrotal Hydrocele: Role of Physical Exam and Transillumination in Diagnosis by Keihani [8] and Transillumination: Shining a light from within by Irfan [9] in BMJ case Reports.

Photography

Photography is easiest if the patient is seated as, depending on strength of the light source, a long exposure may be needed. For high quality photographs use a low digital film speed and place the camera on a tripod to avoid camera shake with long exposures. The key factor in exposure is the strength of the light source and the amount of heat it produces. Almost all light sources produce heat and it is important for the patient's comfort that the light source is only applied long enough for the photograph to be taken and then removed and turned off. If multiple photographs are needed to get the right exposure the light source should be allowed to cool down between images. The stronger the light the more heat it produces and the shorter the exposure. So there is a balance between film speed, light strength and exposure time.

It is routine to take photographs with normal light first, Figure 1 taken with studio flash and then with

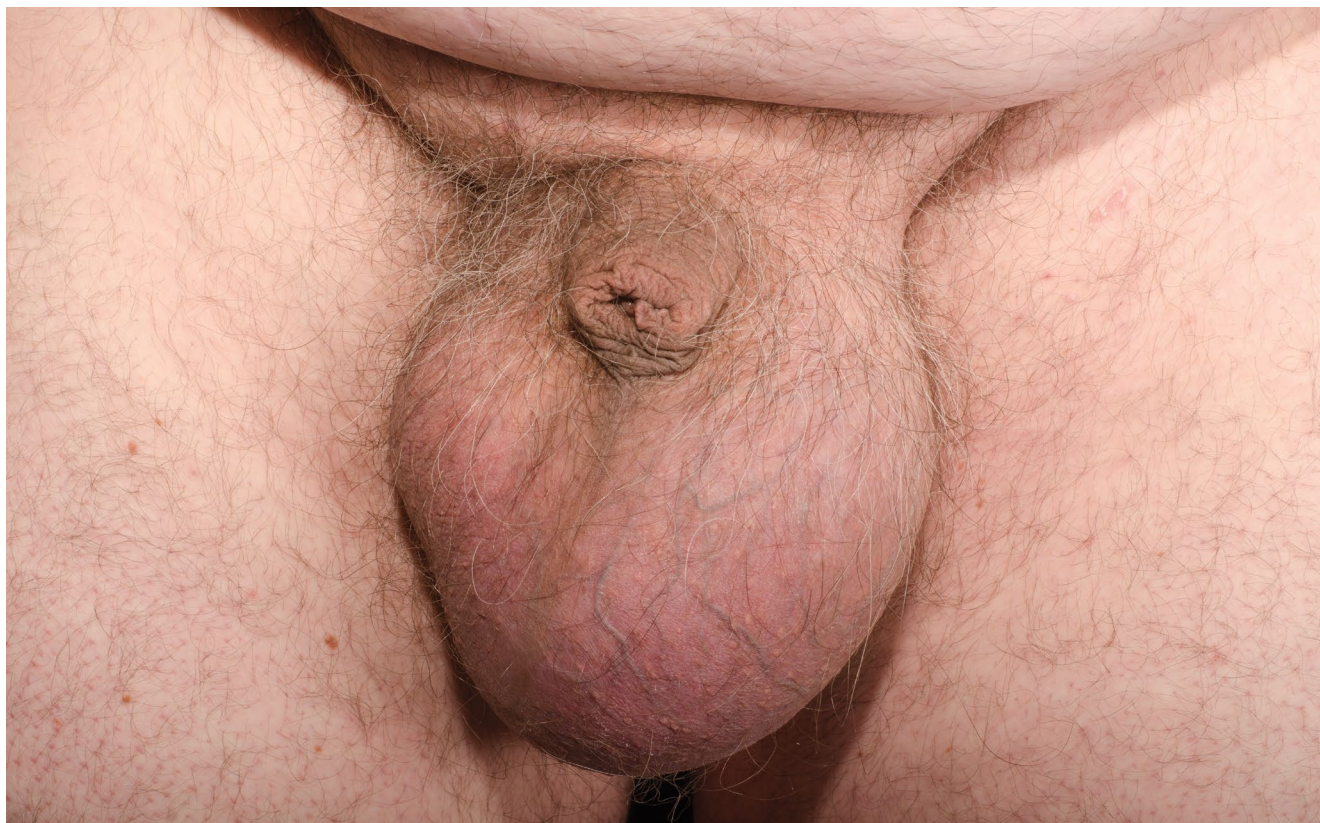

Figure 1: Normal clinical photograph showing hydrocele of the left testicle.

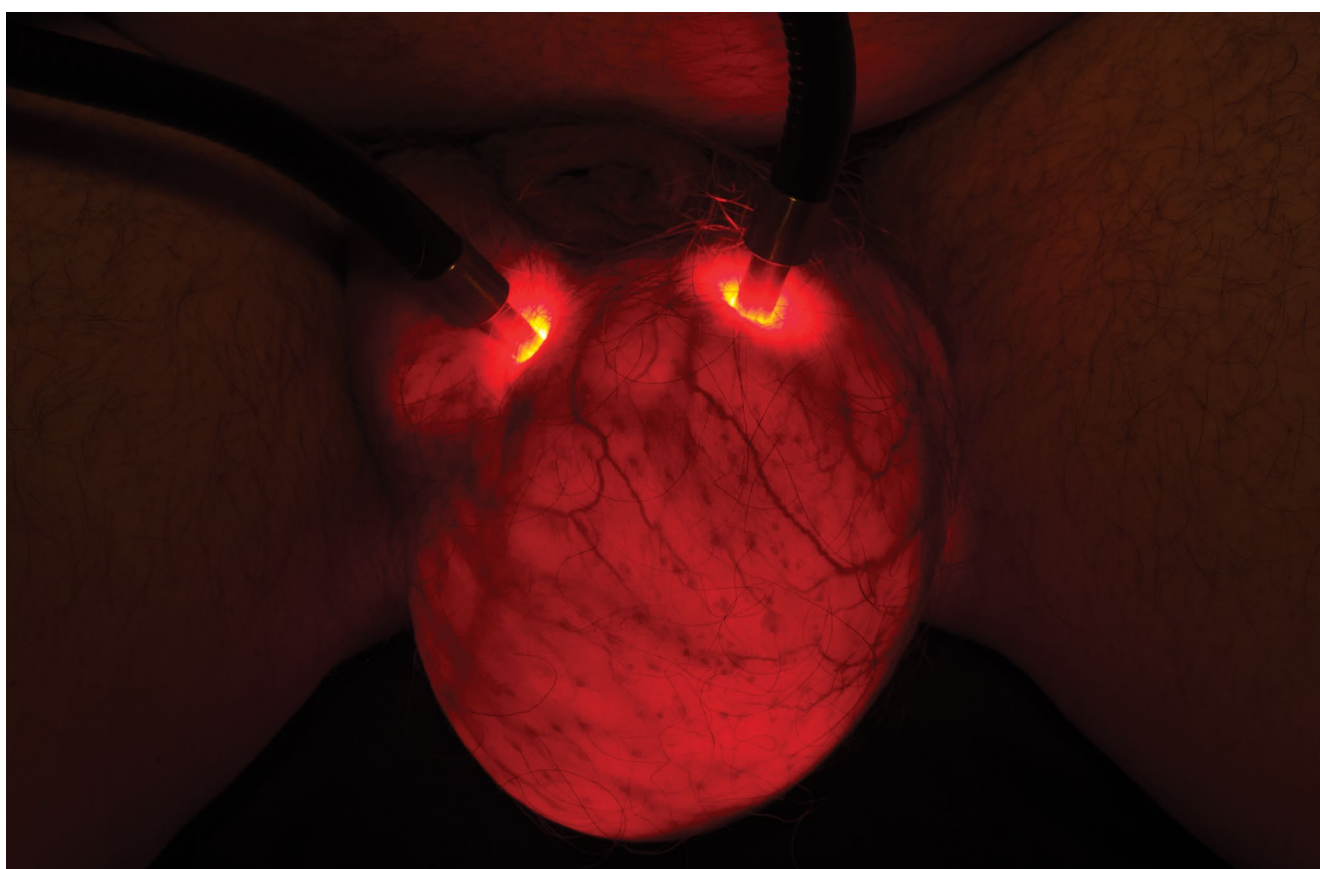


Figure 2: Photograph showing transillumination of hydrocele of the left testicle.

transillumination, [Figure 2](#). It can be difficult to locate anatomical points and features on the testicle when looking at the transilluminated view. The transillumi-

nated view was taken using fibre optic light source with a colour temperature of 3200° K, camera was a Nikon D7000 set at ¼ second at an aperture of f/8, ISO 400. As

the skin and tissues transmit light of long wavelengths, red part of the spectrum, so the colour temperature of the light source is unimportant. Due to this recording with the camera on auto white balance or for daylight will give the same end appearance.

References

1. Bryant T (1873) The practice of surgery. Henry C Lea, p583.
2. Kjersem B, Krohn J (2013) Transillumination imaging of intraocular tumours. *J Vis Commun Med* 36: 26-30.
3. Johns M (1979) Transillumination of the infant skull. *Journal of Audiovisual Media in Medicine* 2: 140-149.
4. Morton R, Miller SS (1981) Infrared transillumination using photography and television (videodioscopy). *Journal of Audiovisual Media in Medicine* 4: 86-90.
5. Ray S (1999) Scientific photography and applied imaging. Focal Press, London.
6. Kaliyadan F & Ashique KT (2016) Nail photography: Tips and tricks. *J Cutan Aesthet Surg* 9: 254-257.
7. Pandita A, Sharma D, Shastri S (2015) Transillumination test: A bedside aid for differentiating meningocele from myelomeningocele: Point of care testing. *Medical Journal of Dr DY Patil University* 8: 276.
8. Keihani S, Hojjat A, Kajbafzadeh AM (2015) Abdomino-scrotal Hydrocele: Role of Physical Exam and Transillumination in Diagnosis. *J Pediatr* 167: 1448-e1.
9. Irfan M, Waldron R, Bolger J, Barry K (2014) Transillumination: shining a light from within. *BMJ case reports*.